تيوي حبولينا

Histiocytoses

- EMid
- Bolognia
- Darnuti

What is Histiocytes: ??

- they are tissue Macrophages that derived from Blood Monocytes (2S) following

BM derived Promonocytes
(precursor cells)

↓

Blood Monocytes
(half life 71 hr)
then:

↓

Migrate to tissues
to differentiate into
2 Types of
Histiocytes

↓

Professional Phagocytes (Macrophages)
2 Types

- Immature Macrophages (Inflammatory Macrophages)
- Resident tissue Macrophages

Funct^

1- phagocytosis
2- Ag presentat^ (via MHC II) to sensitized T-Cells only (not Naieve not Memory)
3- Cytokines product^:
- IL1
- IFN-B
- GMcf

[Cells that responsive to chemotactic stimuli & are attracted to site of inflamm]

(F)
"Ag presenting cells"

↓

Dendritic cells (DC)

- Epidermal "LC"
- Dermal: ↓ Dendrocytes

Cut. dendritic Cells
(Ag presenting cells)

(F) Ag presentat (+++) ± phagocytosis → to 3 T Cell Types

- **Epidermal Langerhan's Cells** — S100, CD 1a, CD 207
 - site: Supra basal (2-8% of Epid. Cells)
 - Morphology: - dendritic
 - pale staining Cytoplasm
 - Convoluted Nucl
 - chic Cytoplasmic granules called "Birbeck granules" (tennis Racquet)
 - Rod shapped e⁻ Terminal Vesicular dilatat^ [tennis Racquet]
 - only in LC ± Hairy Cell. leuk. Cells.
 - → derived from / CM by endocytosis.
 - Funct^: Ag presentat^ to T Cells (Sensitized / Naieve / Memory)
 - How?? by (1). Ag endocytosis
 (2). Ag processing (by lysosomal enz)
 (3). reexpressing Ag on surf. bound ± MHC II → efferent Lymphatics

- **Dermal dendritic Cells**
 - Dermal dendrocytes
 - 2 Types:-
 1- Type I:- (فوق)
 - upper dermal
 - Known Funct^ → phagocytosis, Ag pres^ent
 - factor XIIIa +ve
 - Melanin, Hemosid.
 2- Type II:- (تحت)
 - lower dermal
 - Unknown funct^
 - CD 34 +ve

→ represent Subdomains of endoplasmic reCycling Compartment & form at sites where Protein Langerin Accumulat^

- Receptors of it:-
 - MHC II
 - Fc IgG
 - C3b
 - CD 1 (role in Ag presentat^)
 - S100.

- **S100**
 - MCs → hyperpigmentation
 - LCs
 - Schwann cells.
 - Interdigitating cells.
 - undetermined cells.

- **Factor XIII a**
 - Endothelial → (vascular)
 - Type I dermal dendrocytes. (DF)

- **CD34 :-**
 - Endothelial (vascular)
 - Type II dermal dendrocytes. (DFSP)
 - Mast cells
 - Stem cells.

- **CD45:** Common leukocytes Antigen.

Histiocytosis

Def: reactive or Bg^mg Accumulation of Histiocytes in Many organs. According the the type of infiltrating Histiocytes there are (2 Types) of Histoicytosis → Langerhans : LCs infilt. → Non Langerhan infilt by Cs other than LCs

(LCH) Class I: Langerhans' cell histiocytosis (Histiocytosis X)

Non-cancerous ('reactive') increase in number of Langerhans' cells (histiocytes within the epidermis)

+Ve: S100, CD1a, Langerin (CD207) & birbeck gs.

- Letterer-Siwe disease < 2y
- Hand-Schuller-Christian disease 2-6y
- Eosinophilic granuloma 5-15 skin
- Congenital self-healing reticulohistiocytosis (Hashimoto-Pritzker disease) → Bone

Class II: Non-Langerhans' cell histiocytosis.

Class IIa: Dermal dendritic cell histiocytosis (DDH)

Non-cancerous ('reactive') increase in number of non-Langerhans' cell histiocytes.

Ch BY:
- -Ve < S100, CD1a, Birbeck gs.
- +Ve < CD68, Factor XIIIa

Hist. Xanthogranulomatous reacts.

- Dermatofibroma (DF) (+Ve XIIIa)
- Juvenile xanthogranuloma (JXG)
- Benign cephalic histiocytosis (BCH)
- Generalised eruptive histiocytoma
- Papular xanthogranuloma
- Erdheim-Chester disease
- Progressive nodular histiocytosis
- Solitary reticulohistiocytoma (Solitary Retic.)
- Xanthoma disseminatum

Class IIb: Non-Langerhans' cell, non-dermal dendritic cell histiocytosis

Reactive increase in number of (non-Langerhans' and non-dermal dendritic) histioctyes

- CD68 (Macrophage)
- MAC387 (immature Macrophage)
- HAM56.

- Diffuse plane xanthomatosis
- Reticulohistiocytosis. (+ Giant cells)
- Necrobiotic xanthogranuloma →
- Rosai-Dorfman disease (S100)
- Familial haemophagocytic lymphohistiocytosis
- Familial sea-blue histiocytosis
- Hereditary progressive mucinous histiocytosis

Class III: Malignant histiocytoses

Cancerous change in histiocytes

- Monocytic leukaemia
- Malignant histiocytosis
- True histiocytic lymphoma

Langerhan's Cell Histiocytosis (LCH)

(Histiocytosis -X)

Def. reactive condition in ↻ cells with phenotype of Langerhan's cells Accumulate in various tissues causing damage

Etiopathogenesis unknown but ± :-

① Infect ↻ < TB / HSV 6 (Was found in large N° of patients → ++ LC & ↓ Immunological Control of Histiocyte prolif.

② Immunological (IL17 → fusion bet Giant cells & LCs).

③ Malignancy: LCH cells are clonal cells.

- **General character** :-

⊙ Reactive conditions d+ infiltr. by LCs-like Cells called LCH cells

⊙ all types are → S100 +ve, → CD1a +ve & CD207 = langerin, ↘ Birbeck grs (+ve)

⊙ affect ↻ ±

① Single system e.g (SS-LCH) ← الأشهر
- Skin
- Bone

② Multisystem (MS-LCH) (الأسوأ)
- Skin
- Bone
- L.N
- Liver & Spleen
- Lung
- Blood
- CNS
- CVS

prognosis

→ early onset (<2 y/s & multisystem affect ↻ → Poorer prognosis.

definition :- ≥ 2 organs or organ systems.

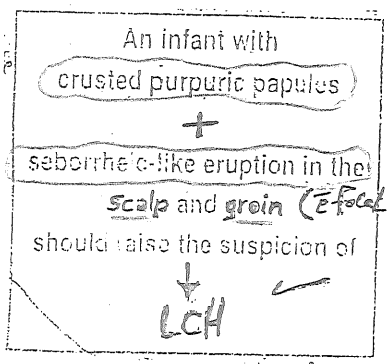
- **Risky organs** :-
 - Spleen
 - Liver
 - Lung
 - Blood (BM) (Hematopoietic)

Langerhan's Cell Histiocytosis:-

(Histiocytosis-X [قديم] → because unknown AE

1- Letterer Siwe dse (Acute disseminated) [LSD]

- Age < 2 Ys
- Cut. : Crusted, purpuric Papules, Vesicules & pustules at scalp & Groin
 - → MM & Nail affect^
 - gingivitis, loose teeth
 - paronychia, dystrophy
- Systemic : (بالترتيب)
 - Bone : osteolytic bone lesions
 - L.N : Lymphadenpathy
 - Lung : Pulm infilt.
 - Liver : HSM
 - Blood : Anemia & thrombocytopenia



- Prognosis:
 - Good (Bg) : if only Bone affect^
 - Bad (Mg) : if early onset, Visceral Affects (HSM, purpura, thrombocy) & Nail affects (syst)

2- Hand-Schuller Christian (HSCD)

(Chr. Multifocal)

2-6 Ys

- Bone lesions (80%)
- Exophthalmos (10%)
- DI (50%)
- Skin lesions
 - Early: LSD like
 - Later: ulcerated plaques at axillae, Mouth & Genitalia
- Uncommon : Visceral affects

3- Hashimoto Pritzker

(Cong. self Healing Reticulohist

- birth or Infancy.
- Cut. only : disseminated reddish brown Nods & plaques ulcer, Atrophic dsypigm. scars.
- Course: self limiting (8-24 ms) then ± recur or → LSD.

4- Eosinophic granuloma (Bg localized)

- 5-15 Ys.
- Bone only: osteolytic lesions at flat bones (Scalp Vault)
 - → ± fracture
- Course: Self limiting or → LSD or HSCD.

Diagnosis of LCH. (3 levels)

1. Histopathology
2. Immunohistochemistry
3. EM

1. Histopathology (LN):

Histopathology of LCH

- in All types: there are LCH Cells ☺ Ch By:
 - Ovoid ↓ Large ē irregular vesiculated
 - → "Kidney shapped Nucleus (d.t central indentation) or Coffee bean (d.t peripheral ind.)
 - Abundant slightly Eosinophilic Cytoplasm.
 - Birbeck grs (50%) [by EM]

In Hashimoto Pritzker:
LCH Cells + multinucleated cell.
→ mid & upper Dermis.

- there are 3 Types of Reactions:

↓ LSD
↓ Proliferative Reaction
LCH Cells infilt. upper dermis & invade epid. in many areas.

PKG
↓ Hand-Schuller
↓ "Xanthomatous Reacl"
- upper dermis
 - → Foamy Histiocytes
 - → multinucleated giant Cells
- EB (++)
- Touton (+)

Eos. Granuloma
↓ Granulomatous
extensive infilt. of LCH Cells ē clusters of
- Eosinophils
- Gian Cells

2. Immunohistochemistry: Both LCs & LCH Cells Show

+Ve:
- S100
- CD1a
- CD207 (Langerin)
- Birbeck grs.

- So How to differentiate ??

- CBC
- LFTS
- BMA
- urine osm.
- XR MRI → other Tests.

NB on LCH

- **Adult LCH:**
 - rare
 - Abnl presentation: Flexural & perianal (Psoriasiform / vesicular & papulovesicular) Crusted lesions.

- **Malignant LCH:**

A. Langerhans cell Lymphoma = (خبيث) Langerhans sarcoma

- Solitary, Lymphoma like Tm
- Poor prognosis
- Path. → atypical dendritic histiocytes.
 - ✓ are +ve (S100 / Neurone specific Enolase)

B. LSD with Malignant outcome:

- Early onset < 2 y.
- Visceral involvement
- Purpura & anemia.
- Clonality & Cytological atypia.

LCs	LCH Cells.
• have dendrites. • Convoluted nucleus • Birbeck grs. (+++) • CD1a + • S100 • CD 207 (Langerin)	• No dendrites (ovoid) • Kidney shapped. • ± birbeck grs (5%) • as LCs + • PNA (peanut agglut.) • PLAP (placental AK. ph.).

• Cause of death: Inf, Systemic affects, Haemo-. Phagocytosis.

Treatment of langerhans cell histiocytosis (revise ē 2012) # gyskn d.s

Single-system disease			Multisystem disease
Skin		Bone	
Children	Adults		
Observation or topical nitrogen mustard	Topical nitrogen mustard PUVA CO_2 laser Thalidomide Isotretinoin	• Surgery • Glucocorticoid injections • Radiotherapy • Monochemotherapy (in multiple bone lesions)	• Monochemotherapy with vinblastine or etoposide, preceded or not by glucocorticoid administration • Nonresponders may be treated with polychemotherapy

• DD of LCH

1. LSD:
 - SD
 - AD
 - Wiskot Aldrich
 - Darier
 - Hashimoto Pritzker
 - Sinus Histiocytosis
 - Hemophagocytic Syndrome

2. HSCD
 - Xanthoma disseminatum
 - JXG.

Non Langerhans cell Histiocytosis

Class IIa- Dermal dendritic cell Hist.

- Juvenile Xanthogranuloma
- papular Xanthoma
- Xanthoma Disseminatum.
- Benign cephalic Histiocytosis (BCH)
- Generalized Eruptive Histiocytoma (GEH)
- progressive Nodular Histiocytosis
- Reticulohistiocytosis (solitary type)
- Others
 - Erdheim
 - Dermatofibroma.

(7) أمراض

- حبيبيات — JXG, BCH — EM: Coma Bodies (Buh) — JXG: Foamy Giant Cells, BCH: No.
- 2 — Generalized eruptive Histiocytoma
 progressive Nodular Histiocytosis (or om.

- Xanthoma:
 - Papular
 - disseminatum

- Reticulo Histiocytosis. (Giant cell Retic.)

Juvenile Xanthogranuloma (JXG)

(Nevoxanthoendothelioma)

- The most common type of Histiocytosis (of all)
- Age: 90% Childhood → M > F
 10% Adulthood → M = F (So the term Juvenile is not Accurate).
- it may affect:
 - Cut. (Cutaneous)
 - Extracut.
 - Skin.
 - MM (rare) → ulcerating nodules at lat. tongue & palate
 - Eye
 - Lung
 - Liver
 - CNS
 - CVS
 - Testes.
 - Associations

(Systemic organs)

- Cut. Manifestations: (80–90%) appear in the First year (1st year) & usually Solitary lesion.
- lesion: Dome-shapped, reddish-brown or yellow Nodule usually affect the head & Neck (also ± upper trunk & extremities) → Fate: Childhood → 3–6 Y → resolve ± Scar, Pigm.; Adult: → more persisted

Adult JXG
Ch By:
- Solitary
- persistent.

- According to size of lesion it may be Classified as:
 - Micronodular (papular): < 1 cm (<1cm) & Multiple
 - Macronodular: > 1 cm, single or few (1–2 cm)
 - Giant: > 2 cm.

Cryoferm
Sign: JXG affect the Nose → diffuse enlargement.

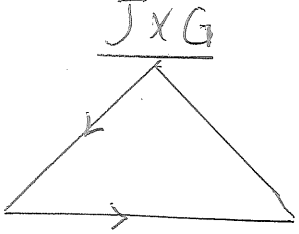
- Clinical varieties:
 - in site: Lips, Toe, Scrotum.
 - in lesion:
 - Lichenoid
 - Keratotic
 - Pedunculated
 - Clustered
 - S.C
 - Plaque
 - Cryoferm

• **Visceral Manifestations**: the most common affected organs are:

↳ **Eye** (< 1%): Iris affect → Anterior Chamber Angle → Glaucoma & Hyphema → Blindness.

Eye is the most common extracut. organ affected

- **Lung**
- **Liver** → Cause of death (± Spont. Resolution)
- **CNS**
- **CVS**
- **Testes** **
- **Triple Association**:



CALM
- 20% ass.
- 3% Leukem

NB: • JXG ass. ē CALM in ≈ 20% → ↑ risk.

• JXG + NF1 → 30 times ↑ risk of Leukemia (Chr. Myelogenous)

• **Diagnosis** (3 levels)

Touton Giant Cells

- **Histopathology** (upper dermal SC)
 (Xanthogranulomatous)
 - Foamy Cells (Histiocytes)
 - Touton Giant cells
 - ± inflamm. cells
 - Fibrosis (late)
- **Immuno-histochemical** (Dermal Dendrocytes)
 - +Ve: CD68, XIIIa (13a), HAM56
 - −Ve: CD1a, langerin (CD207), S100
- **EM** Histiocytes ch BY:
 1. **Nucleus**: irregular vesicular ē Pseudopauds
 2. **Cytoplasm**: Coma shaped bodies (Birbeck granules)

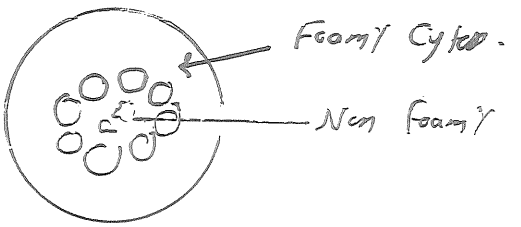
Treatment (Not needed as it is self limiting).

- **Excision** → For Cosmetic reasons.
- **Ocular lesion** → Topical Cs.
- **Systemic lesion** → · Cs + Cyclosporine
 · Chemo therapy

NB . **Touton Giant Cell**

. Wreathy arrangement of Nuclei (ring) around Foamy Cytoplasm (in center) & Foamy Cytop. outside The Nuclei.

. Center : non foamy
. rim : foamy.



• Papular Xanthoma

- Generalized, yellowish, asymptomatic "small Papular" skin lesions on / ... & head.
- No → Coalescence of lesions.
 → Lipid Impairment
 → Visceral involvement ✓
 → D.I.

(in adults MM is affected.)

- **Pathology**: Foamy (Xanthematized) Histiocytes + Touton Giant cells.

[NO - Inflamm. cells]

- **Fate** < **Children**: Spont. resolut° at (1-5Y.) → anetoderma like
 Adults: Persist.

Xanthoma Disseminatum

(Montgomry Synd.)

- usually Male < 25y. (but any age 8m.-80y.)

- Triad of:

1. SKin lesions
2. MM lesions (50%)
3. D.I (40%)

Face
Flexures
MM
D.I

→ ē Coalescence

2. MM lesions at:

- Oropharynx → dysphagia
- Larynx → dysphonia & obst
- Conjunctiva & Corneal → ± Blindness.

3. D.I
- d.t hypothalamic & pituitary stalk affect
- mild & Transient.

- SKin lesions: hundreds of Bilat., Symmetrical yellow or reddish-brown Papules & (Plaques) on Flexures, Face & Eye-Lid → ± Coalesce → Verrucous.

- Course: may → Resolve / persistent / progressive. [good prognosis except for Laryngeal Lesions]

- NB: it may be ass. ē MM; Here it will be presented by "Sclerotic Variant": Extensive Keloid like at Trunk, Abd. & limbs.

- HP: dermal Infilt. ē (Spindle) Histiocytes, Foamy Histiocytes, Touton Cell & other Inflamm. Cells.

- Rx:
 1. Air-way obst. → Radioth.
 2. Clofibrate & (Cyclophosphamide) ↓
 3. Excision, Cryo, IL & dermabrasion.

نسوي جولوبيا

Histiocytoses

- EMed
- Belgrano
- Darnuti

what is Histiocytes: ??

they are tissue Macrophages that derived from Blood Monocytes (a) following

BM derived promonocytes
(precursor cell)

↓

Blood Monocytes
(half life 71 hr)
then:

↓

Migrate to tissues to differentiate into 2 Types of Histiocytes

- Professional Phagocytes (Macrophages)
 - 2 Types:
 - Immature Macrophages (Inflammatory Macrophages) [cells that responsive to chemotactic stimuli & are attracted to site of inflamm.]
 - Resident Tissue Macrophages.
 - Function:
 1. phagocytosis
 2. Ag presentation (via MHC II) to sensitized T-cells only (not Naieve nor Memory)
 3. Cytokines production:
 - IL1
 - IFN-β
 - GMCF.
- (F) "Ag presenting cell"
 - Dendritic cells (DC)
 - Epidermal "LC"
 - Dermal: Dendrocytes

Cut. dendritic cells
(Ag presenting cells)

(F) < Ag presentat^ (+++)
± Phagocytosis
↓
To 3 T cell Types ←

↙ ↘

Epidermal Langerhan's cell

- Site: Supra basal (2-8% of Epid. cells)
- Morphology: . dendritic
 . Pale staining Cytop.
 . Convoluted Nucl.
 . Chic cytoplasmic granules called "Birbeck granules"
 . Rod shapped ē Terminal vesicular dilatat^ [tennis Racquet]
 → represent Subdomains of endoplasmic reCycling Compartment & Form at sites where protein Langerin Accumulat.
- only in < LC ± Hairy cell. leuK. cells.
- derived From ↓ CM by endocytosis.
- Funct^: Ag presentat^ to Sensitized T Cells < Naieve / Memory
- How?? by (1). Ag endocytosis
 (2). Ag Processing (by lysosomal enz.)
 (3). reexpressing Ag on surf. bound ± MHC-II → ē fferent Lymphatic.
- Receptors of it:
 . MHC II
 . Fc IgG
 . C3b
 . CD1 (role in Ag presentat^)
 . Slan.

Dermal dendritic Cell

- Dermal dendrocytes ↓

- 2 Types:

(1.) Type I:
 . upper dermal
 . Known Funct^ < Phagocytosis, Ag pres. ent
 . Factor XIIIa +ve
 . Melanin, Hemosid.

(2.) Type II
 . lower dermal
 . Unknown Funct^
 . CD34+

- **S100**
 - MCs
 - LCs
 - Schwann Cells.
 - Interdigitating Cells.
 - undetermined cells.

- **Factor XIII a** → Endothelial
 Type I dermal dendrocyte. (DF)

- **CD34**:
 - Endothelial
 - Type II dermal dendrocyte. (DFSP)
 - Mast cells
 - Stem cells.

- **CD45** Common leukocyte Antigen.

Histiocytosis

Def reactive or Mg Accumulat^ of Histiocytes in Many organs. According the the Type of infiltrating Histiocytes there are (2 Types) of Histiocytosis — Langerhans : LCs infilt. / Non Langerhans infilt. by cells other than LCs

Class I: Langerhans' cell histiocytosis (Histiocytosis X)

Non-cancerous ('reactive') increase in number of Langerhans' cells (histiocytes within the epidermis)

. +ve : S100, CD1a, Langerin (CD207) & birbeck gns.

- Letterer-Siwe disease
- Hand-Schuller-Christian disease
- Eosinophilic granuloma
- Congenital self-healing reticulohistiocytosis (Hashimoto-Pritzker disease)

Class II: Non-Langerhans' cell histiocytosis.

Class IIa: Dermal dendritic cell histiocytosis

Non-cancerous ('reactive') increase in number of non-Langerhans' cell histiocytes.

. Ch^ By:
. -ve < S100, CD1a, Birbeck gns.
. +ve < CD68, Factor XIIIa
. Hist. Xanthogranuloma kno react^.

- Dermatofibroma (DF)
- Juvenile xanthogranuloma ✓ (JXG)
- Benign cephalic histiocytosis ✓ (BCH)
- Generalised eruptive histiocytoma ✓
- Papular xanthogranuloma
- Erdheim-Chester disease
- Progressive nodular histiocytosis
- Solitary reticulohistiocytoma (Solitary Retic.)
- Xanthoma disseminatum ✓

Class IIb: Non-Langerhans' cell, non-dermal dendritic cell histiocytosis

Reactive increase in number of (non-Langerhans' and non-dermal dendritic) histioctyes

. CD68 (Macrophage)
. MAC 387 (immature Mo-Crophage)
. HAM 55

- Diffuse plane xanthomatosis
- Reticulohistiocytosis. (+ Gross Tumour)
- Necrobiotic xanthogranuloma →
- Rosai-Dorfman disease (Sinus)
- Familial haemophagocytic lymphohistiocytosis
- Familial sea-blue histiocytosis
- Hereditary progressive mucinous histiocytosis

Class III: Malignant histiocytoses

Cancerous change in histiocytes

- Monocytic leukaemia
- Malignant histiocytosis
- True histiocytic lymphoma

Langerhans Cell Histiocytosis (LCH)

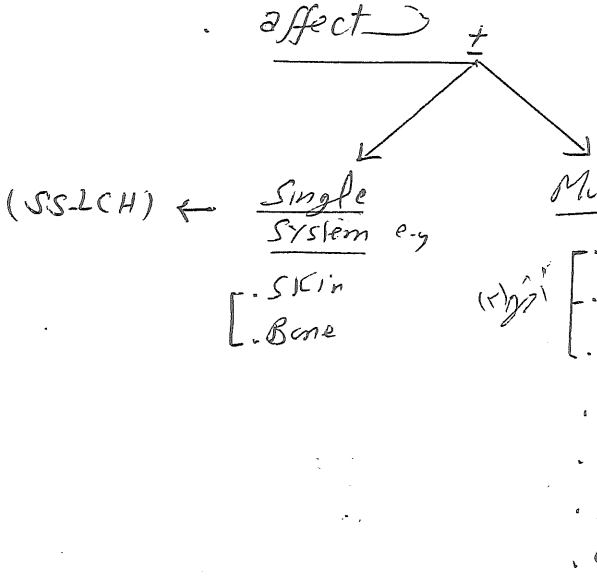
(Histiocytosis X)

Def. reactive condition in which cells with phenotype of Langerhans cells Accumulate in various tissues causing damage.

Etiopathogenesis unknown but ±:

1. **Infect** ← TB, HSV 6 (was found in large No of patients → ++ LC & ↓ Immunological control of Histiocyte prolif.
2. **Immunological** CIL17 → Fusion bet Giant cells & LCs).
3. **Malignancy**: LCH cells are clonal cells

- **General character**:
 - reactive conditions d.t infiltr. by (LCs-like) cells called LCH cells
 - all Types are ← S 100 +ve, CD1a +ve & CD 207, Birbeck grs. (+ve)
 - affect → ±



- **prognosis**: early onset (<2) & multi system affect → Poorer prognosis.
- **definition**: ≥ 2 organs or organ systems.
- **Risky organs**: . Spleen, . Liver, . Lung, . Blood (BM) (Hematopoiesis)

Langerhan Cell Histocytosis:

(Histocytosis - X (قبل سنة))

1. Litterer Siwe (Acute disseminated) [LSD]

- Age < 2 ys
- Cut. : Crusted, purpuric Papules, Vesicales & pustules at scalp & Groin
- MM & Nail effect:
 - gingivitis → loose teeth
 - Paronychia → Dystrophy
- Systemic:
 - Bone: osteolytic bone lesions
 - L.N: Lymphadenopathy
 - Lung: Pulm infilt.
 - Liver: HSM
 - Blood: Anemia & thrombocytopenia

An infant with crusted purpuric papules + seborrheic-like eruption in the scalp and groin (ج فوق should raise the suspicion of ↓ LCH

- Prognosis:
 - Good (Bg): if only Bone effect.
 - Bad (Mg): if early onset, Visceral Affect: HSM, purpura, thrombocy. & Nail effect

2. Hand-Schuller Christian (HSCD)

(Chr. Multifocal)

2-6 ys

- Bone lesions (80%)
- ± Exophthal-mos (10%)
- DI (50%)
- Skin lesions
 - early: LSD like
 - Later: ulcerated plaques at axillae, mouth & Genitalia
- uncommon: Visceral affect.

3. Hashimoto Pritzker (Cong. Self Healing)

(Bg)

- birth or Infancy.
- Cut. only: disseminated reddish brown Nods. & plaques ± ulcers (Atrophic) dyspigm. scars.
- Course: self limiting (8-24 ms) then ↑ recur → LSD.

4. Eosinophic granuloma (Bg localized)

- 5-15 ys.
- Bone only: osteolytic lesions at Flat bones (Scalp Vault) → ↑ Fracture.
- Course: Self limiting (87) → LSD or HSCD.

Benign Cephalic Histiocytosis (BCH)

· 2-12m
· 2-8y.
· No ← MM Visceral HT Teuton or Giant Cell

· Onset: 2-12 m. ⟶ resolve at: 2-8 y.

· Clp: yellowish-red Flat macules & papules at Face & Neck (± → Chest & trunk) ⟶ more flattening & Hyperpigm ⟶ resolve spont at (2-8 y.) but may leave Hyperpigm.

· No ← MM or Visceral HT affect (Case report DF).

Coma Shapped Bodies → JXG, BCH

· Diagnosis: Histiocytes rich in coma shapped Bodies (No Touton nor Giant Cells)

· HT: Self-limiting.

(1) · Progressive Nodular:

· Any age
· Papules & Nodules (Sp. at Face → Lesions: Nose, Lips)
· Persistent
· ± M.M

(2) Generalized Eruptive Histio.

· Adults.
· papules only ± dark blue (Dark Line)
· resolve spont. ± e ← dyspigm. / Scar.

(3) Papular Xanthoma

HP

(1) Prog. Nodular: (No effective HT)

· Early: Foamy & Scalloped Histiocytes.
· Late: Spindle Shapped arranged in storiform Pattern. (2S)
· occasional Giant Cells.

(2) Generalized Eruptive:

· Neither Foamy Nor Giant Cells.

... ك تشوكيرية

Eruptive Syringoma

((DD))

(1) Eruptive Syringoma.
(2) Eruptive Xanthoma
(3) Papular "
(4) Progressive Nodular Histiocyt.
(5) Generalized Eruptive Histiocy.
(6) disseminated Variant of BCH.
(7) Mastocytosis.

· Neither Foamy Nor Giant Cells:

· BCH
· Generalized Eruptive.

Class II b Histiocytosis

(Non LCs, Non dermal dendritic Histiocytosis)

- Reticulohistiocytosis
- Necrobiotic XG
- Diffuse plane Xanthoma
- Sinus Histiocytosis ē Massive L.N
- Indeterminate Cell Histiocytosis.
- familial hemophagocytic Lymphohistiocytosis
- familial sea blue histiocytosis
- Hereditary Progressive Mucinous... Histiocytosis (Hist. with Mucinosis)
- Histiocytosis with Necrosis
- Indeterminate cell Histiocytosis.

PV: yes

- Multicentric
- 2 xanthomas — JXG / Plane xanth. (Normolipemic)
- Sinus Histiocytosis.
- malakoplakia

Reticulohistiocytosis

(3)

- Solitary
- Multicentric
- → Cong. Self. Healing (Hashimoto-Pritzker).

• M = F	• F > M
• Young adults	• 4th decade
• Class IIa	• Class IIb

(1) **Solitary Reticulohistiocytoma**: [illegible] DF > [illegible] (2) Head + [illegible].

- usually, single, < 1cm, yellow-red nodule on head → resolve spont.
- rarely: multiple without systemic affect

(2) **Multicentric RH**: → Pentad (lipoid dermatoarthritis) (5): skin, joint, mm, Mg, Hyperlipid

Associations:

1. **Skin lesions** (90%): skin colored-red or brown nodules & papules. Mainly Acral.
 - Spontaneous resolution ± occur in 5-10ys.
 - Subtle form: Flat macules & papules of dorsal hands. Very similar to LM
 - Coral bead Ear pinna Pentad
 - تذكر:
2. **MM**
 - oral, Nasal, pharyngeal & ocular.
3. **Polyarthritis**
 - Symmetric, Erosive & Mutilating.
 - Typically affects Hands.
 - (3:1), F > M, 4th decade.
 - ٥٪ عبل كبير
- II. Juxta-articular, in proximity of affected joints; dorsal Hands, Feet, extensor elbows
- (2). Face & Scalp: ear pinna (thi). ± Lamina face
- (3). Nails: periungual "Coral bead" & Nail dystrophy.

4. Mg (30) — Stomach, Bronchogenic, Cervical.

5. Hyperlipidemia (30)

Associations

- Autoimmunity
 - Systemic vasculitis
- +ve tuberculin test
- ↑ ESR, IgG, fever, ↓wt.
- heart, Eye, Lung, GIT lesions

DD of Juxta-articular Nodules
- MCRH
- R.A
- Sarcoidosis
- Xanthomatosis
- Gout.

- Histopathology: oncocytic Histiocytes. (↑ mitochond → acidophilia of cytoplasm) + Giant cells + Others:
 - Lymphocytes
 - Eos.
 - Plasma cells
 - Fibrosis (old lesions)

 (i.e. pink/oncocytic cytoplasm)
 - Contain lipid
 - +ve PAS.

 skin / Synovial Biopsy.

- Grenz Zone is +ve

Giant cells:
- Cytoplasm (what?)
 - Ground glass (Homogenous = Non Foamy) & Eosinophilic.
- Nuclei
 - 1–12
 - arranged — Central, peripheral or Haphazard

- Immunohist:
 - +ve Histiocytes of — ATPase, Lysozymes, α1 Antitrypsin
 - Classical Monocyte / Macrophage
 - Markers are +ve: CD 68, HAM56 & Mac 387
 - Factor XIIIa — +ve in solitary. −ve in Multicentric.

- Treatment
 - CS + Azathioprine
 - Cyclophosphamide & CyA
 - Recently: Alendronate / Anti-TNFα

- Necrobiotic Xanthogranuloma → see granulomas
- Diffuse plane Xanthoma → " Xanthomas.

Sinus Histiocytosis with Massive L.N (Rosai-Dorfman dis).

- usually affect children & young adults. (10-30) (أكثر شيوعاً عند الأطفال والشباب)
- Course: indolent, self limited ē protracted course marked by remission & Exacerbat.

C/P = Nodal affect + Extranodal affect + Association:

- Nodal affect:
 - 90%
 - Massive, bilat., painless Cervical L.N (Chic)
- Extranodal affect:
 - 40%
 - Commonest is the skin 10%
 - Skin affect ± the only finding ēcut L.N (Cut. Sinus Histiocytosis)
 - C/P: red-brown, Xanth. omatous Macules, Papules, Nodules usually at: Eye lid / Malar area.
- Association:
 - Fever
 - ↑ESR
 - ↑IgG (Hypergammaglobulinemia)
 - ↑ Neut.
 - Immune dysfunct.
 - (Rh) = [15%]
 - Usually: anti-RBCs antibodies & Joint dis.

So Rosai-Dorfman Synd. ±:
- Nodal (from interdigitating Histiocytes)
- Cutaneous.

- Bad prognostic signs:
 1. Autoimmunity.
 2. disseminated Nodal dis.
 3. Visceral aff.: renal ē Lower RT involvement, Hepatic.

- Prognosis: 60% → persist
 20% → resolute
 10% → die.

Diagnosis

Pathology → Biopsy → Nodal / extra-Nodal

Histiocytes +

- Cytop.: foamy
 Eos., Abundant
- Nucleus: Large vesicular
- Feathy border

infiltrating Sinuses of L.N or dermis of skin.

Inflamm. Cells +

- lymphocytes
- plasma cells.

"Lymphophagocytosis"

Emperipolesis (Chic but not unique).

(phagocytosis of intact Lymphocytes & plasma cells by Histiocytes)

Immunohistochemical:

- CD68, HAM 56 & Mac 387 (+ve)
- +ve S100
- CD1a −ve

- DD → disease ē Massive L.N:
 - Lymphomas (H. & non H.)
 - CLL.
 - Metastases.
 - Infectious L.N
 - Kikuchi's dis: ?? [Histiocytic Necrotizing Lymphadenitis]
 - CIP: Fever + Tender Cervical L.N
 - asian, young women.
 - Normal: WBCs, ESR & HCT.
 - Path: LN shows
 - Necrotic foci
 - Cellular popular ⊃ of large blastic Lymphocytes & Histiocytes.

ESE: Histiocytes engulfing Apoptotic...

of Rosai-Dorfman

- No ## (self-limiting)
- Indications: destructive, disseminated dis, physical Compromisal ⊂
- Types: . surgical
 . radio
 . Cs
 . Alkylating Agents
 . Vincristin
 . Vinblastin
 ↙ thalidomide (±)

Indeterminate Cell Histiocytosis

(LCH ليس non LCH يجمل يضايقني)

- Children & Adults.
- Self limiting
- CIP < Generalized: GEH like
 Solitary: single, soft, Erythem. lesions
] Ulcerate ± occur.
- rare: ocular & visceral affect
- Path: as LCH (Vacuolated / Xanthomatised Histiocytes throughout dermis)
- Immunohist / +ve CD1a, S100
 — +ve CD68, HAM56 & Mac387.
 \ −ve birbeck granules.
- ttt (not required as it self limited)
 (±) · PUVA
 · Chlordeoxyadenosine.

(Ref P3) • Familial hemophagocytic lymphohistiocytosis

- AR
- death ēin 12 ms
- wide spread infilt. of many organs by Lymphocytes & histiocytes showing prominant "Cytophagocytosis".

- Clp
 - Fever
 - URTI
 - UGITI.
 - Immunological abnormalities
 - Non Specific Maculopapular rash.
 - hyper cytokinemia: ↑ IFN γ - TNF-α, IL 6
- IH BM & Hemopoietic stem cell transplantation.

• Sea Blue Histiocytosis: < Inherited . rare SKin
Acquired : pgm. Cmod.

- ± familial inherited or Acquired.
- Clically: histiocytic cell contain cytoplasmic granules that stain (blue-green) ē (Azure) Geimsa & blue with May-Grunwald stain
- these Histiocytes infilt. systemic organs & / skin. →
 - papules
 - Eyelid swelling
 - patchy gray pigm. of face & trunk.

Inherited Type ± ass. ē: Neurological abnormal.

Malakoplakia

d.t Abnl immune response to ↑ E. Coli

- rare Immunodeficiency dis. of Macrophages.
- usually affect Urinary Bladder & ± other sites < GIT / skin
- Cut. affects is rare: perianal & perigenital papules, Nodules, Plaques & Tms ; Pink. Yellow ± ē central dimple or sinus
- HP: Hansmann Histiocytes: Histiocytes ē chic Michalis-Guttmann Bodies (Stain +ve For < Cat Iron & when fully developed → like Owel's eye).

(Ref P4)
- Surgical → then Antibiotic (Soltrin)
- Vit C
- Clofazemine.

- **Hereditary progressive Mucinous Histiocytosis**
 (Histiocytosis with Mucinosis)

 - AD.
 - Start in Childhood (1st decade) & Tt Age
 - Skin Colored – red brown Nodules that affect < Nose, Hand, forearm, thigh.
 - Path: . Epithelioid & Spindle shapped Histiocytes
 . Mucin deposit (by Alcian or Toludin Blue).
 - No < systemic affects, spont. resolut, Ht.

- Histiocytosis & Necrosis = "Kikuchi dis"
 (See DD of Sinus Histiocytosis) –

- Erdheim-Chester dis. (rare)
 - Any age
 - Cut Manifs: yellow nodules & indurated plaques at Perorbital, Trunk, scalp & Extremities.
 - Systemic manifs:
 - DI
 - Bony lesions (Bone ache of legs)
 - Exophthalmos.
 - CNS, lung, adrenal, renal & testes.
 - death >50%

تقسيم بوتين — Bg. Melanocytic Neoplasms

- Freckles (Ephelides)
- Lentigenes
- CALM
- Becker's Nevus
- Halo
- Nevus Spilus
- Dermal Melanocytosis

→ See pigmentation

- Cong. Melanocytic Nevus
- Acquired Melanocytic Nevi
- Spitz Nevus
- Atypical (Dysplastic) Nevus

Others:

- Melanocytic Nevi of Genital & Flexural Skin
- Melanocytic Nevus of Acral Skin.
- Recurrent Melanocytic Nevus (Pseudo-Melanoma)
- Pigmented Spindle Cell Nevus.

Melanocytic Nevi

2017

(Moles)

- Def: Bg neoplasms or Hamartomas composed of Type of MCs called Nevus Cells

2 Main differences bet if. & NL MCs:

1. present in Nests (NL MCs present singly)
2. Has No dendrites (Except in Blue Nevi).
3. Doesn't deliver Melanin to surrounding KCs.

Nevus Cells Has 3 Types (CELN)

- Type A (Epithelioid like)
 - in lower epid & upper dermis
 - Epithelioid like (tall or large simulating epid. KCs)
 - Contain Considerable amount of Melanin.
- Type B (Lymphocytoid)
 - Mid dermis
 - Lymphoid like (small lymphocytes)
 - Very little or No Melanin.
- Type C (Neuroid)
 - Lower dermis
 - Neuroid like (schwann cell like or fibroblast like): Elongated spindle nucleus
 - Rare Melanin

- origin (Embryology) either:
 1. Dual origin: Nevus Cells of { upper dermis: originate from MCs; lower: Schwann Cells }
 2. Single origin: from Neural Crest it gives { Nevoblast → Nevus Cells; Melanoblast → Leptomeninges, Uveal Tract, Dermis & Hair; Schwann cell }

(Nevus نيفس
Nevus جمع)

Classification of Melanocytic Nevi

(ONN2)

1. Acc. to: Age of onset: Congenital / Acquired
2. Histopathological: Junctional, Dermal, Compound & Combined (مركب)
3. Atypical & Typical.

1. Classification of Melanocytic Nevi acc. to: Age of onset

- **Congenital (< 2 y.)**
 - True Congenital: appears at birth
 - Congenital like or Tardive Nevi: (develop in 2 y. after birth)
- **Acquired (> 2 y.)**
 - Not at birth
 - Usually: start at childhood or early adulthood (1st 3 decades)

Types: (According to Size)

- Small < 1.5 cm diameter
- Medium: 1.5 - 10 cm
- Large: 10 - 20 cm
- Giant: > 20 cm
- Satellite

(2013)
- Lower
- Elevated
- Dark
- ± Hair.

- HP Types: Compound

Clinical Types:

1. Junctional: جمع جانبي
2. Compound: جانبي وجلدي
3. Intradermal: جلدي فقط (skin color) وقد يكون بارز وقد يكون مسطح

- HP: Junctional, Compound & Dermal.

Difference bet Cong. & Acquired Nevi by HP

- Cong. Nevi ch BY: Nesting of Nevus Cells:
 - Extend deeply to deep dermis & S.C.T
 - clusters around Adnexae & BVs
 - Infilt. bet Collagen bundles.
 - Nevus-cell poor Subepid. Zone

Cong. Nevi
- Cong. Melanocytic N.
- Spilus Nevus
- CALM
- Ota.

Acquired Nevi

C.I.P (1) Junctional Nevus

- Junctional prolif. of Nevus Cell at DEJ
- Clinically: Just Macular Pigmentation (No elevation)
- Nevus Cells are: Epithelioid like

(2) Compound Nevus

- Nevus Cells proliferate both at DEJ & at dermis (upper)
- Nevus Cells are Lymphocytoid like
- Slightly elevated (Papule) Darkly Pigmented.

(3) Dermal Nevus

- Nevus Cells proliferate at Dermis (No Junctional Activity)
- Nevus Cells are Neuroid like.
- Mo: Really elevated Papule / Nodule & light or No Pigmentation

تذكر كلمة Nevus عند Cells.

- The Nevus may start Junctional ثم مع الوقت Compound or Intradermal So Elevation isn't a sign of Mg. Malignant Transformation in Cong. > Acq.

Congenital Melanocytic Nevi (CCMN)

- Types according to size: small < 1.5 cm diameter, Medium: 1.5-10 cm, Large: 11-20 cm & Giant > 20 cm.
- Giant Cong. Melanocytic Nevus: ((Bathing Trunk))
 - 5% → Incid of MM (Compared to < 1% in other Types)
 - 10% → ass. ē Neurocut. Melanocytosis specially if. — large, Axial, Ass. ē Satellite
 - 80% → ± ass ē Satellites.

- Neurocut. Melanosis (NCM)

Def. either — Cong. Bathing Trunk (Giant N.) or > 3 small. Medium Sized "Lesions" (Satellites)

+ Meningeal Melanosis = Neurocut. Melanosis

- Symptomatic → ↑ ICT
- Asympt. (most cases) → (81) MRI

* Complications:
1. disfigurement
2. Mg
3. dryness & itching: ↓ Seb. & Sweat glo.

- ## of Cong. melanocytic Nevi surgery, or other times (Laser, Shave) are ass. with Recurrence

Halo Nevus

(Sutton's Nevus = Perineroid Vitiligo = leukoderma Acquisitum Centrifugum) (LAC)

- **Epidemiology:**
 - **Age** usually < 20Y (Casually Acquired)
 - **Associat.** — **Comm:** Vitiligo (20%) & other halo nevi (25-50%)
 less: atypical nevus & Melanoma.
 - **Course** — **Halo:** occurs over period of ws-ms.
 Nevus: → occasionally persist → then repigmentation of Halo
 → More likely involute (ws-ms) → persistance of Halo for ms-ys (or may ↓↓)

Theory of development of the Halo

2 theories:

(Now favored)

① Immune response against antigenically altered Nevus Cells ass. ē Tm progression: (Exp)

هذه بتفسر كيف إن المريض عنده Atypical Nevus بسبب Immunologic response ass. ē Tumorigenesis

② CMI & HI against non specifically altered Nevomelanocytes & possible Cross reactivity ē distant Nevo melanocy

CIP — * **Nevus:** Typical brown or dark, flat or raised ī surface scaling or Crusting.

"its Acquired Melanocytic Nevi"

- **Typical Mean** =
 - A
 - B
 - C
 - D

= 3-6 mm (largest diameter) regular well defined border Homogeneous color. Symmetrical

* Halo: start as erythema → Hypo or depigm.
(May be Examined ē WL) [Symmetrical in Width].

Types of Halo Nevus

1. Inflammatory
 - +ve infilt. by HP
 - هاتف لواوها
2. Non-Inflammatory:
 - -ve Infilt.
 - ش هاتف
3. Halo Nevus without Halo
 - +ve infilt.
 - clinically: No Halo.

VNZ)

Halo dermatitis or ECZ = Myerson's Nevus

- Nevus surr. by ECZ. may occur alone r ass. ē Halo nevus

Typical Cs

- DD — Halo Dermatitis (ECZ.)
 - Halo depigm:
 - Melanocytic proliferat ē Halo
 - By Atypical MM
 - Blue
 - Spitz
 - Cong. Nevi
 - Atypical Nevi
 - blue Nevi
 - Spitz Nev.
 - Melanoma & Melanoma Metastases (Asymm. Halo)
 - Non Melanocytic lesions ē Halo
 - DF
 - SK
 - plane warts
 - Molluscum
 - BCC.
 - L-P.
 - Psoriasis
 - Sarcoidosis

Treatment

- All cases look for (1) other Halo nev. (25%-50%)
 (2) Vitiligo (20%)
 (3) Atypical Nevi
 (4) Melanoma (or history < Pregnancy FH)

Then if Nevus
- Typical
- Atypical → Histo Path

- Any pt > 40 y. ē Multiple Halo nev. → examine for Melanoma (ocular Mc

Dermal Melanocytosis (Dermal Melanocytic Nevus / Cerulioderma)

Pathophysiology

- due to arrest of MC Migration from dermis to epid → dendritic & (Fusiform) MCs.
- due To optical effect (Tyndall phenom.)
 → Slate-brown or blue-black or Cerulioderma
- Types: (Ybiam)
 1. Mongolian Spots.
 2. Nevus of Ota
 3. Nevus of Ito
 4. Blue Nevus.

① Mongolian Spot

- onset: at birth or 1st week, rarely Childhood → with regress in childhood.
- Etiopathogenesis: MCs reach dermis at lumbar then either migrate to epid. or die
 Except at scalp, extensor distal extremities, sacral area.
- why appears blue?? Tyndall phenomenon
 or Slate-brown (Cerulioderma)

(Slate اللون الرمادي المزرق)

Def. ↓ reflectance in ! longer wave length region Compared E- the Surrounding Skin

- longer wave-lengths: as: red, orange, Yellow
- shorter " " as: blue & Violet → reflected

CIP Most Common Sites:

- Sacrococcygeal
- Lumbar
- buttock
- back

extra Sacral Variant (Aberrant Variant) → More persistent.

NB. Extensive lesions → خلقي → Phakomatosis pigmentovascularis Types II & IV

- Treatment
 1. Reassurance; self limiting
 2. Laser

- Nevus of Ota (Oculodermal Melanocytosis)

. At birth (50٪) or Acquired (around puberty)

. 80٪ are females

. May affect:
- Skin: at distrib. of Trigeminal Nerve brs (Facial)
- Eye: sclera → iris mamillo ! (but no visual affect) ⇒ Glaucoma
- MM: Nasal Mucosa.

Q-Switched Laser

. اولها تشوف طبيبة (حيث ما فيه مرض في العين)

→ Take Care of Eye as:
- Glaucoma
- Melanoma (Most melanoma are ocular)

. Bilateral Variant is called Nevus of Hori":

: الفرق بين unilat. Nevus of Ota
- ♀ 20-70y.
- at Zygoma
- No ocular or Nasal affect
- ± mis diagnosed as Melasma

- Nevus of Ito

as Ota Nevus but differs in its distribut⁻ at shoulder & upper arms (i.e. distal ⅓ of Post. Supraclavicular & lat. brachial cut.

Blue Nevus (&its variants)

- onset: Acquired (childhood or adolescence) → rarely congenital.
- Etiopathogenesis: عدم مرونة أو انتقال الـ Melanocytes من الـ Epid. إلى الـ Dermis في أماكن معينة هي الـ Sites of Blue Nevi.
- Types: (1.) Common Blue Nevi: ("ordinary") (0.5-1cm.)
 - Blue or Blue-Black papule < 1 cm
 - usually at dorsal Hands & feet (+ face & scalp)
 - path: NL NCs singly or in nests in Dermis & Periappendageal.

(2) Cellular Blue Nevi: [May → MM]
 - Nodule or plaque ≥ 1-3 cm.
 - Buttocks, Sacrap > Extremities & Face.

(3) Mg Blue Nevi [Cut. Melanoma arising (in) or having features of Blue Nevus].
 - Cut. Melanoma arise on Top of any Blue Nevus or develops de novo
 - Large, Multilobulated plaque at scalp.

- DD: Conditions Simulating Blue Nevi: Traumatic tatto, Compound Nevus, DF, Venous lake, Pigmented BCC

Treatment:
1. if: < 1cm, Stable & No Features of Mg & in Typical sites → No Rx
2. if: large, progressive, multinodular or plaque → Excision. (?melanoma)

(2012) # Spitz Nevus

(Epithelioid & Spindle cell Nevus / Benign Juvenile Melanoma)

- Def: Type of Compound. Bg Nevi affects children & resembles Malignant Melanoma both < Clinically & Pathologically
- Etiopath: May develop denovo or on Top of existing Melanocytic Nevus.
- Epidemiology:
 - Age: 5a/ < 10ys & 7a/ → 2nd decade (العشرية الثانية)
 - Sex: M = F.
 - Race: fair skin.
- Clip: Single, dome shapped red or pigmented Papule or Nodule usually on legs & Face (in adult → any site) (U.V excess vascularity & minor Pigm) in childhood
 - the lesion: show rapid growth (1cm in 6ms) → Then → static For Years but often disappear Spontaneously

- Clinical Varieties
 1. The lesion is:
 - Polypoid.
 - Crusted.
 - Telangiect.
 2. Multiple:
 - Agminated = grouped
 - Disseminated
 3. Atypical
 4. Mg = Spitzoid Melanoma.

- Hx: Surgical Excision.

HP

- Appx: Nests of Epithelioid & Spindle cell shapped MCs
 - arranged in clusters & Giant Multinucleated Nevus cell among them.
 - & Vertical Fascicular (bundles) arrangement.

+

- Kamino Bodies: Eosinophilic, PAS +ve Globules Among Nests (degenerated KC)

.. Atypical / Dysplastic Nevus = Clark's Nevus

Def. : Acquired compound Nevus whose clinical & Histological definitions are Controversial & Still evolving

- **Etiopath** : (1) Idiopathic (Sporadic)
 (2) familial (Genetic)
 (3) UVL
- **Types:** (1.) Sporadic — Any Age; 1-10 lesions; Risk of MM : 6%
 (2.) familial — 1st degree relatives; 10-100 lesions; Risk (Cumulative)

- was previously named « Dysplastic Nevus Synd » now called Familial Atypical Mole & Melanoma (FAMM) Synd

- **Criteria For Dx:**
 (i). FH of malig. melanoma (of 1st or 2nd degree relative)
 (ii). > 50 Nevi some of which are clinically atypical.
 (iii). Dysplastic Histopath.

- **Hp**
 1. Odd looking Atypical
 MCs: Epithelioid (End KCs)
 Spindle shaped (Elongated)
 Proliferate Singly & in Nests at DEJ & derms (Pagetoid) & may bridge or join Together
 2. Fibrosis; Bus; Infill.

(لو زيادة) إذا بتشك فيها بعمل excision "الكل": If Mg → Excision.

	Common Acq. Nevi (Benign)	Atypical Nevi	Melanoma
Asymmetry	• Mirror Image Symmetry	• Some Asymmetry	• Asymmetrical
Border	• Regular & Well defined	• Irreg. & ill defined (not scalloped or Notched)	• Very < irreg. ill defined. (Scalloped or Notched)
Color	• Homogenous regularity. (tan - dark brown or skin colored)	• Somewhat haphazard (irregularity of Pigm.) & 2-3 Colors [tan, brown, dark brown] But (+) gray, blue, white	• Haphazard (more complexity)
Diameter	< 5 - 6 mm (<5)	3 - 15 mm (>5)	any but usually > 5mm

Malignant Melanoma
(MM)

Def Neoplasm of Melanocytic origin that begins as prolif. of Atypical MCs at DEJ
Then by Time ⟶ Invade Dermis & S.C.T
⟶ ± Lymphatic & Blood spread.

- **Age** : . usually > 60 yr.
 . rare in prepubertals
 . in children usually arise ← on Top of Giant or Cong Axial Nevi (Acq. MM)
 Transplacental Spread from the affected mother (Cong. MM)

- **incid** : . highest rate in Australia (30-37 / 100 000)
- **Mortality** : . 75% of deaths from Cancer is (2.5) MM
 . في أمريكا يموت واحد كل ساعة بسبب MM
 في سنة 2018 حالة (9118)

- **Risk factors**: (1.) Fair Complexion (skin I & II)
 Chr. (2) UVL Exposure
 (3) precursor Nevi (pre Mg) ← Dysplastic Nev. (FAMM), Numerous Atypical Nevi, Giant Nevi (>5)
 (4.) Past Hx or Family Hx of MM
 (5) Genetic Mutations. (Genetic-وراثي)

70% of MM develop on Top of NL skin

- **NB** . Small-medium sized Cong. Nevi 1% ⟶ MM
 . Giant bathing Trunk 5% ⟶ MM

- . other organs can be affected by MM (sites of MCs
 MM: Eye, Ear
 . orbit
 . oral & nasal cavity
 . Meninges
 . Vulvae
 . vagina
 . urethra.
 Eye
 Ear

Types

(4) Main clinicopathological Types + others (HL)

In situ Melanoma
(represent Early Radial Growth phase) (CIP) Patch

- Lentigo Maligna (LM)
- Acral lentiginous Melanoma (ALM)
- Superficial spreading " (SSM)

Invasive Melanoma
(represent Late Vertical Growth phase) (CIP: Nodule)

- LM Melanoma ← (≃ 15 / (5–20 y)) — LM
- Invasive (ALM) ← (6–12 m) — ALM
- Invasive (SSM) ← " — SSM

- Nodular Melanoma
(No Insitu radial growth phase, starts as Invasive).

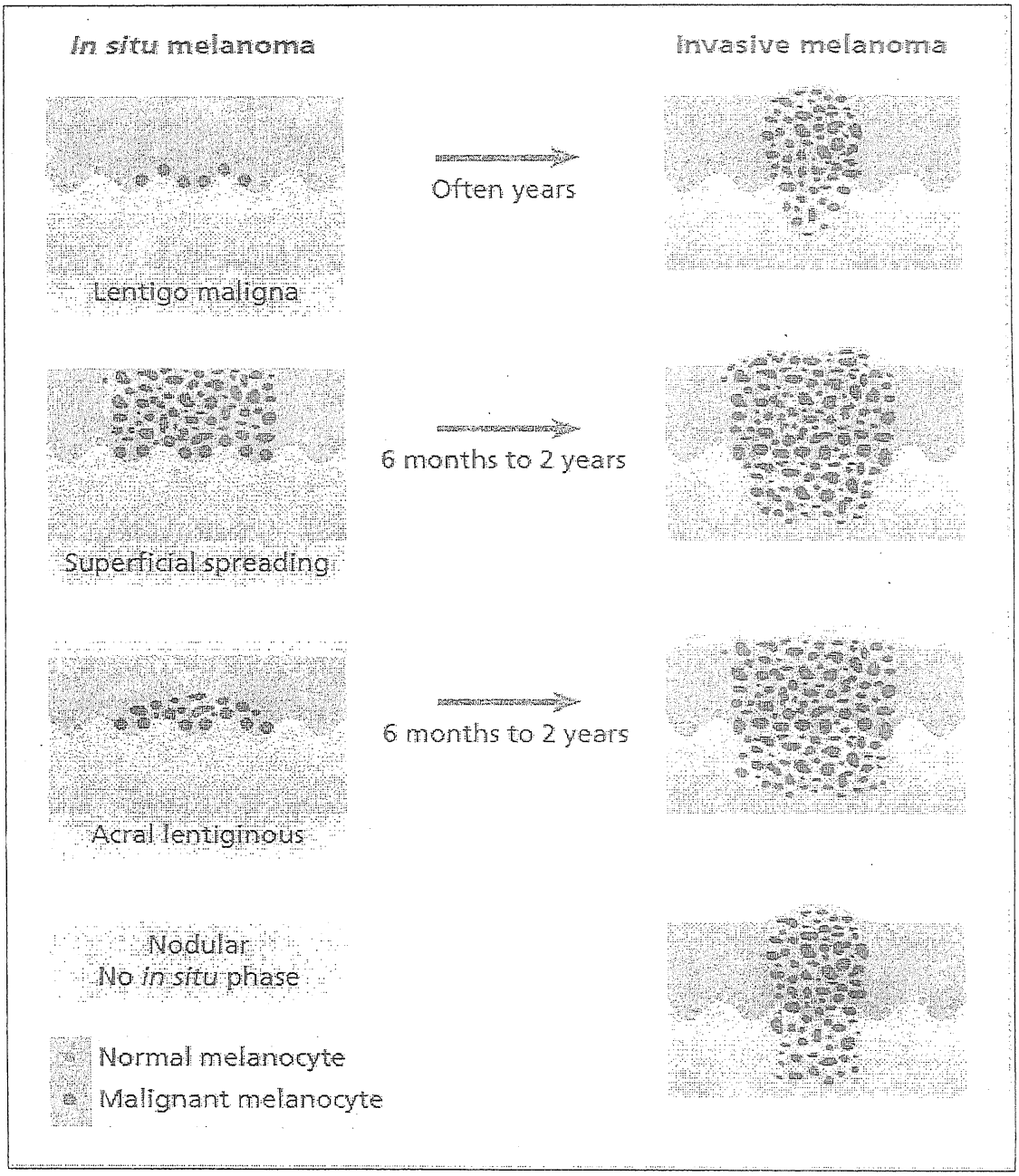
- Other Types: (GSM)

Incid
- Age
- Prog.
- Site — Face ← L → LMM
- Acral ← A → ALM
- N → Nodular
- ♂: upper back
- ♀: lower leg.
- S → SSMM

(اللنتجرة) (LANS)

10 %	6th–7th decade	best
5 %	7th decade	Poor
15 %	5–6th "	Poor
70 %	4–5th "	Poor

- what is the:
 - Commonest type ?? & rarest Type.
 - best prognosis ??



* Histology of the different types of melanoma.

General Clp of MM

Has 2 clinicopathological stages

Early stage or lesion:

- Clinically: Hyperpigmented Macule / Patch that shows ABCDE &/or Glasgow 7-point checklist criteria.
- Pathologically: Mg prolif. of Melanocytes in Horizontal direct. at BMZ (in situ) without dermal Invasion [Early radial growth phase]

Late stage

- Clinically: Pigmented Nodule (± non-pigmented)
- Pathologically: Dermal Invasion by Mg. Melanocytes [late Vertical growth phase].

MM usually asympt.; but ± itchy or Tender (e.g. ALM)

The ABCDE of melanoma

A	Asymmetry (2 halves of the lesions are not symm.)
B	Border irregularity (edge: ragged, Notched or Blurred)
C	Colour variation (not uniform; ± أسود - أحمر - أبيض - أزرق - بني)
D	Diameter over 6 mm
E	Evolving. Dramatic Changes in Size & Shape.

Glasgow 7-point checklist

Major features	Minor features
▪ Change in size ▪ Irregular shape ▪ Variable colour	▪ Diameter >7mm. ▪ Inflammation ▪ Oozing ▪ Change in sensation

SSC

Discussion of Each Type

lentigenes → ABCDs change → called lentigo Maligna (insitu MM) → LMM (invasive).

• LMM

- Incid, Age, as before.
- Site: Face Sp. Cheeks & ears (skin around HF).
 - on Top of Sundamage Skin (on Top of Lentigenes)
- progression to invasive MM ≃ 5% (Macule → Nodule)
- Cip (نادر) — Early Macular radial growth phase (ie ABCD Glasgow.
 late Nodular Vertical " "
- Varieties: Desmoplastic - Neurotropic - Myxoid

• ALM:

(Commonest Type in blacks 50% (lot in whites))

- Incid:
- Age: —
- Site: Acral (Palms, Soles, Nails (Bed & periungual), on digits & w.l bearing Heels) → Tender plantar Nodule → Biopsy
 - "glaberous skin"
 - Melanonychia (+ve Hutchinson sign)
- Cip: نادر

• Nodular M:

- Starts as Nodular; radial growth Stage (No Macular radial growth phase)
- Incid, age, site (Any) → as before.

Cip
- Varieties:
 - Classical lesion (Pigmented Nodule)
 - Ulcerated "
 - Amelanotic
 - Non Pigmented Nodule (DD ← BCC, PG, Perlma)
 - the Classical lesion in Albinics.

• SMM: → نادر

- Other Variants of MM

(1) Ocular MM : ē Nevus of Ota

(2) Mucosal : mouth, Nasopharynx, Larynx, Vagina & Anus.

(3) Nevoid Melanoma : (No) epid. involvement.

(4) HP Variants:

- Desmoplastic → fibrous Stroma
- Neurotropic → perineural invasion → Pain
- myxoid → Myxoid Stroma.

(5) Animal type : "Hess" ... النوع الحيواني

(6) Spit Zold

(7) Blue

- Hutchinson Sign : Subungual Melanoma with extension of Pigmentation To Lat & proximal Nail fold.

(السوري)

- Pseudo Hutchinson sign : نفس التعريف لكن هيش بيحصل Benign وليس Melanoma مع Condition.

- Hutchinsons in Dermatology ??

(سؤال امتحان) Diagnosis of MM. (For Melanoma L.N Metast)

1. Clinical — ABCDE / Glasgow - 7 Point Checklist.
2. Dermascopy
3. HP & Immunohistochemistry
4. SLNB (Sentinel L.N Biopsy)
5. Metastatic work up.
6. Staging of MM

HP

Jr. ① LMM

- Junctional prolif. of Atypical (Mg) spindle shapped MCs → dermal Nests.
- Adnexal involvement
- Solar Elastosis
- Lymphocytic infiltrate
- little Pagetoid scatter.

② ALM: → Epidermis shows: as LMM +

- Hyperplastic
- Pagetoid scatter: Atypical MCs present singly (most common) or in an irregular shapped Nests at all levels of Epid.

No/little pagetoid → LMM / ALM

+ve pagetoid → SMM

③ Nodular M: (No radial growth)

i.e.



, dermal Invasion that Connect immediately ē overlying Epid ē NO morphologic abnormality in adjacent epid. on either side of / Nodule.

④ Superficial spreading.. (pagetoid Melanoma).

- dermal Nests ē Atypical cells in / Suprabasal layer of epid. (singly or in clumbs) → Simulating EMPD.

Buckshot pattern.

→ Nerve ↑ Severe pain.

⑤ Desmoplastic, Neurotropic & Myxoid: 3 variants of LMM describing the Stroma surrounding the Nest.

⑥ Nevoid (small cell Melanoma): No epid. Affects ē dermal Invasion by Nevoid cells.

⑦ Animal Type: Blue-black Nodule ē sheets of Atypical Spindle Cells & Heavy dermal Melanin.

Sheep ← horses.

لازم تقرير الباثولوجي حتى

عامل تعليق على هذه النقاط

- Diagnosis (نوع)
- Breslow Thickness (depth)
- Clark's Level of Invasion
- Lympho, vascular or Neural Invasion, ulcers
- Mitoses
- Margins.

1- Breslow thickness

The Breslow thickness is reported for invasive melanomas. It is measured vertically in millimetres from the top of the granular layer (or base of superficial ulceration) to the deepest point of tumour involvement. It is a strong predictor of outcome; the thicker the melanoma, the more likely it is to metastasise (spread). (5)

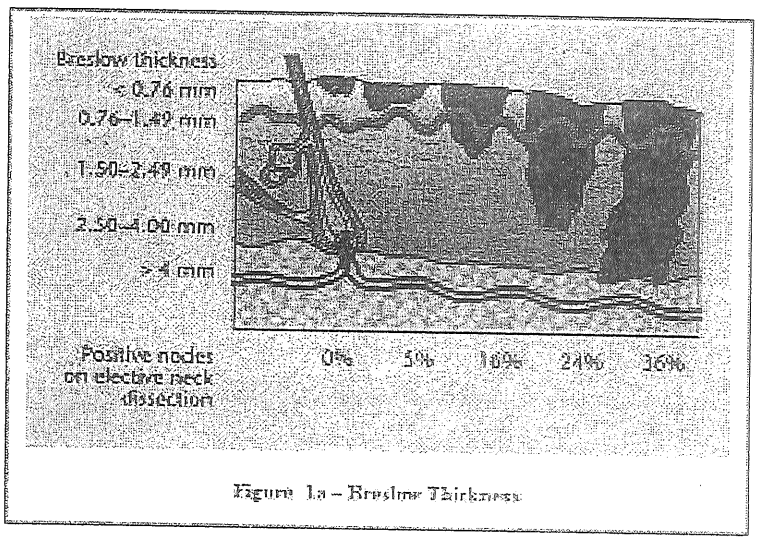
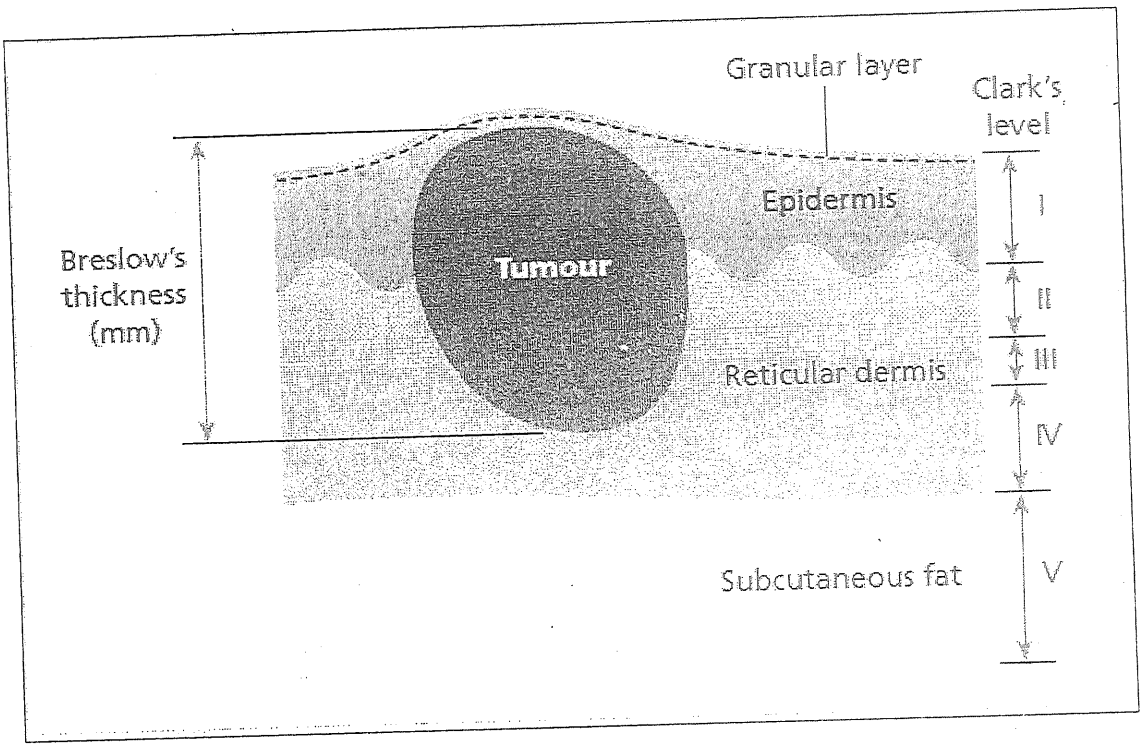


Figure 1a – Breslow Thickness

2- Clark"s level of invasion (5)

Level 1	In situ melanoma
Level 2	Melanoma has invaded papillary dermis
Level 3	Melanoma has filled papillary dermis
Level 4	Melanoma has invaded reticular dermis
Level 5	Melanoma has invaded subcutaneous tissue

The deeper the Clark level, the greater the risk of metastasis (secondary spread). It is useful in predicting outcome in thin tumours, and less useful for thicker ones in comparison to the value of the Breslow thickness.



* Schematic representation of Breslow's and Clark's methods of microstaging malignant melanoma.

- Immunohistology
 (Immunohistochemistry)

- S100 (Ca binding protein):
 - Very sensitive for MCs & Melanoma
 - Most viable for Identifying Spindled M.
 - NB: expressed also at: nerve cells & Langerhan's Cell

- HMB45/gp100:
 - Melanosome Specific Glycoprotein gp100
 - Specific for MCs & Nevus cells.
 - of limited benifit ?? false -ve (35%) & Heterogenous staining pattern.

- Melan-A / MART-1
- Tyrosinase

] of limited sensitivity

③ SLNB: (هام جدا)

↓

. done for staging of regional L.N

. Indication. ① Breslow depth ≥ 1 mm

② presence of < ulceral / lymphovascular Invasion / High Mitoses

. Nodal Metastases يعني إيه؟ (مهم)

N2C
- ① dermal / S.C Lymphatics in ≤ 2 cm from the 1ry Tm → Called "Satellite Metastases".
- ② dermal / SC Lymphatics in > 2 Cm from the 1ry Tm but not beyond the region of L.N → Called "In Transit Metastases"
- ③ Regional L.N Metastases may be Macro-Metastases (Causing clinical Enlargement) or Micro Metast. (LN clinically NL but Histological involve

4. Metastatic Work up.

. Indications (2S)
① Breslow depth / Thickness ≥ 4 mm
② . presence of: ulcerated or lymphovascular Inv.
③ +ve SLNB
④ symptomatic patient < depth > 4mm / Stage > IIC.

. Invs.
. CXR
. LDH (Important) → Marker of Stage IV
. CT / MRI
. others: PET, PCR, S100, HMB-45.

Serum = Marker of Metast.

(5) Staging of MM

طريقة مبسطة وطريقة

3- American Joint Committee on Cancer (AJCC) cutaneous melanoma staging guidelines (2009).

Stage	Characteristics
Stage 0	In situ melanoma
Stage 1	Thin melanoma <2 mm in thickness
Stage 2	Thick melanoma > 2 mm in thickness
Stage 3	Melanoma spread to involve local lymph nodes
Stage 4	Distant metastases have been detected

N

MK

الطريقة الموصى باتباعها حاليا

Stage	TNM Classification	Histologic/Clinical Features	5-Year Survival Rate, %
0	Tis N0 M0	Intraepithelial/in situ melanoma	100
IA	T1a N0 M0	≤1 mm without ulceration and mitotic rate < 1/mm^2	97
IB	T1b N0 M0	≤1 mm with ulceration or mitotic rate ≥1/mm^2	91-94
	T2a N0 M0	1.01-2 mm without ulceration	
IIA	T2b N0 M0	1.01-2 mm with ulceration	79-82
	T3a N0 M0	2.01-4 mm without ulceration	
IIB	T3b N0 M0	2.01-4 mm with ulceration	68-71
	T4a N0 M0	4 mm without ulceration	
IIC	T4b N0 M0	>4 mm with ulceration	53
IIIA	T1-4a N1a M0	Single regional nodal micrometastasis, nonulcerated primary	78
	T1-4a N2a M0	2-3 microscopic positive regional nodes, nonulcerated primary	
IIIB	T1-4b N1a M0	Single regional nodal micrometastasis, ulcerated primary	54-59
	T1-4b N2a M0	2-3 microscopic regional nodes, nonulcerated primary	
	T1-4a N1b M0	Single regional nodal macrometastasis, nonulcerated primary	
	T1-4a N2b M0	2-3 macroscopic regional nodes, no ulceration of primary	
	T1-4a/b N2c M0	In-transit met(s)* and/or satellite lesion(s) without metastatic lymph nodes	
IIIC	T1-4b N2a M0	Single macroscopic regional node, ulcerated primary	40
	T1-4b N2b M0	2-3 macroscopic metastatic regional nodes, ulcerated primary	
	Any T N3 M0	4 or more metastatic nodes, matted nodes/gross extracapsular extension, or in-transit met(s)/satellite lesion(s) and metastatic nodes	
IV	Any T any N M1a	Distant skin, subcutaneous, or nodal mets with normal LDH levels	< 20
	Any T any N M1b	Lung mets with normal LDH	
	Any T any N M1c	All other visceral mets with normal LDH or any distant mets with elevated LDH	

lines of Treatment of MM

(خطوط ٣)

→ Surgical Excision

Excision + SLND + Adjuvant IH → indication

Stage: III & IV

Chemotherapy:

Immunotherapy: IFN α2b, Ipilimumab, GMCSF, Vaccines

Radiotherapy.

Retinoid Therapy.

Vitamins.

Only surgical Excision & Safety Margin: For melanoma < 1 mm depth & No. ulceration, Lymphovasc. Invasion & low mitoses.

Excision + LND (SLND)

- For T1s è:
 - (i) ≥ 1 mm depth
 - (ii) ulceration, Lymphovasc. invasion, Mitotic rate ≥ 1/mm²

Stage IIB (2-4mm), IIC (>4mm) & III ← Node+

- IFN-α 2b (FDA)

Recent Treatments

Melanoma Vaccines:

- Certain HLA & Tm. Ass Ag → ↑↑ NK & HI → Kill Melanoma cells.
- little S.E as Compared to Other Adjuvants.

BRAF Inhibitors: (الدكتورة تعرفها بالتفصيل)

Vemurafenib (FDA 2011)

- Melanomas show Mutation in certain Pro as BRAF & NRAS → So Inhibition of these Mutated Proteins → Treat MM.
- BRAF Genes are Proto-on

1. Iry Melanoma Hf

2 Hf of Regional Metast Melanoma

(A) LN dissect

Management of Region al (L-N)

- Excision & Safety Margin depends on Breslow's depth:

(JAAD)

SURGICAL TREATMENT OF PRIMARY MELANOMA	
Thickness	Excision margins (cm)
In situ	0.5
<1 mm	1.0
1–4 mm	2.0 + SLND
>4 mm	2.0–3.0 + SLND + Adjuvant

ELND (Elective L-N dissect)

- Excision of Clinically or rad. NL draining L.N (No improvement in Survival rate & Carry Risk of Complicat — Inf. (Hematoma, Lymphoedem, disturb Imm. again MM)

NB: only 1/2 or of pt ē Tm > 1mm ēout evidence of Metast. (Clinically or radiologic) → Show MiCro metastasis.

(ELND)

SLND (Selective LND or Sentinel LND)

- blue dye is injected ID at Tm. Site → initially drain to Specific Node(s) called Sentinel (1-2) Node

Technitium Soft &

Biopsied (SLNB) Biopsy.

- +ve Tm Cells → Complete L-Node dissect (Sentinel or Selective Lymphadenectomy) & Further Staging
- -ve Tm Cells → No further Surgery.

NB

- SLND
- less Traumatic
- ELND (because
- 2or show MiCro
- Lymphoscin, high
- draining L-N
- SLN
- Hand-held ga
- Counter & Vi
- Inspect
- Inspect (Hot blue SLN)
- (1) H&E
- (2) Immu Histoch (Sico &
- (3) RT-PCR

So Any Tm ≥ 1mm Thickness, Do Iry Tm Excision + Intraoperative SLND (AJCC) also if ulcerat or Invasion.

What happens at follow-up?

The main purpose of follow-up is to detect recurrences early but it also offers an opportunity to diagnose a new primary melanoma at the first possible opportunity. A second invasive melanoma occurs in 5-10% patients; an unrelated melanoma in situ affects in more than 20% of melanoma patients. The Australian and New Zealand Guidelines for the Management of Melanoma (2008) make the following recommendations for follow-up for patients with invasive melanoma.

- Self skin examination
- Regular routine skin checks by patient's preferred health professional
- Follow-up intervals are preferably six-monthly for five years for patients with stage 1 disease, three-monthly or four-monthly for five years for patients with stage 2 or 3 disease, and yearly thereafter for all patients.
- Individual patient's needs should be considered before appropriate follow-up is offered
- Provide education and support to help patient adjust to their illness

The follow-up appointments may be undertaken by the patient's general practitioner or specialist or they may be shared.

Follow-up appointments may include:

- A check of the scar where the primary melanoma was removed
- A feel for the regional lymph nodes
- A general skin examination
- A full physical examination
- In those with many moles or atypical moles, baseline whole body imaging and sequential macro and dermoscopic images of melanocytic lesions of concern (mole mapping)

In those with more advanced primary disease, follow-up may include:

- Blood tests, including LDH
- Imaging: ultrasound, X-ray, CT, MRI and/or PET scan.

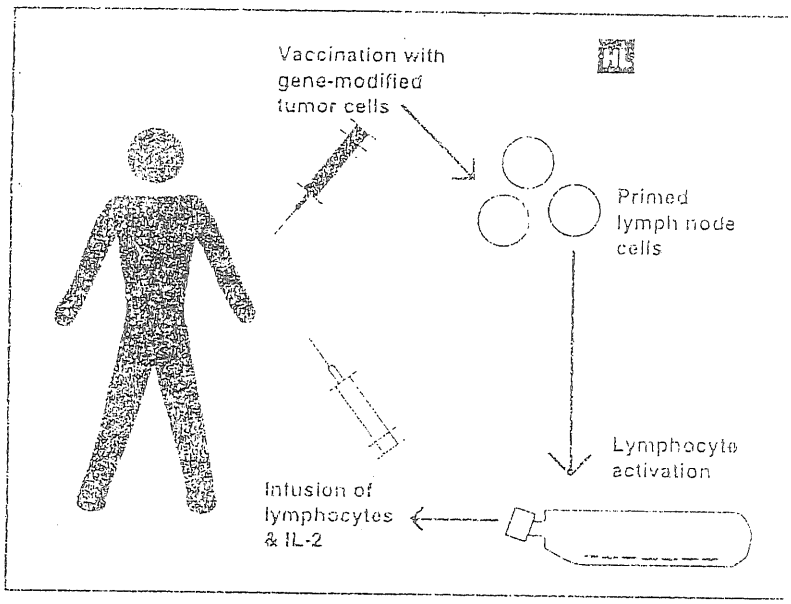
Tests are not typically worthwhile for stage 1/2 melanoma patients unless there are signs or symptoms of disease recurrence or metastasis. And no tests are thought necessary for healthy patients who have remained well for 5 years or longer after removal of their melanoma, whatever stage.

What is the outlook?

Melanoma in situ is not dangerous; it only becomes potentially life threatening if an invasive melanoma develops within it. The rates of melanoma in situ are not reported by cancer registries. The risk of spread and ultimate death from invasive melanoma depends on several factors, but the main one is the measured thickness of the melanoma at the time it was surgically removed.

The Melanoma Guidelines report that metastases are rare for melanomas <0.75mm and the risk for tumours 0.75–1 mm thick is about 5%. The risk steadily increases with thickness so that melanomas >4 mm have a risk of metastasis of about 40%.

New Zealand statistics gathered by the Cancer Registry between 1994 and 2004 revealed 15,839 invasive melanomas. Of these, 52% were under 0.75 mm in thickness, 22% were between 0.76 and 1.49 mm, 15% were between 1.5 and 3 mm in thickness and 11% were more than 3 mm in thickness. Thicker tumours were slightly more likely to be diagnosed in males, and more likely in older people than younger ones.



(VB) Limb perfusion:

- Circulat° of affected limb (U) isolated → Blood slowly heated → Reinfused to the limb again ē high doses of "Melphan| (+ or) ē'out TNFα or IFNγ.
- when the limb circ. is isolated from the remaining Systemic Circ. → Much highe doses of therapeutic agents can be administered without marked Systemic

2. Types of Mast Cells: → (3) ← C.T / Mucosal

Type	Type of Enzyme	
1. T Type	Tryptase	. Mucosa of < GIT / RT
2. C Type	Chymase	. Skin & L.N (SL)
3. TC Type	Tryptase & Chymase	. Skin & GIT (submucosa) (SM)

3. Mast Cells Stimuli (Secretagogues):

Mast cell secretagogues	
Immune stimuli	**Non-immune stimuli**
• IgE-mediated • C3a, C4a, C5a, • IL1 • TNF (tumor necrosis factor)	• Drugs (i.e. opiates) • Radiocontrast media • Physical stimuli (heat & irradiation) • Neuroenteric peptides

→ direct Histamine Liberators ??

- Aspirin
- Strabeiy
- Vancomycin
- C5

4. Mast Cells Mediators:

preformed mediators (granules derived)
- Histamin
- Heparin
- Chemotactic Factors < (E) (N)
- Tryptase
- Chymase.

- Serotonin
- Serin.

Newly Formed Mediators (eicosanoids) ↑ (membrane derived).
- PAF
- PGD2
- LTC4
- LTD4
- LTE4

- Cytokines:
 - IL4, 5, 6, 8
 - TNF-α
 - SCF.

NB Mast Cells Secretions → Mediators / Cytokines

- Tryptase & Chymase: + C3 < C3a → ++ Mast Cells / C3b → ++ alternative C. pathway
- Chymase: ++ Mast Cell degran.

5. Histamin Receptors: 4 Types

Receptor Type	Major Tissue Locations	Major Biologic Effects
H_1	smooth muscle, endothelial cells	acute allergic responses → VD & permeability
H_2	gastric parietal cells	secretion of gastric acid
H_3	central nervous system	modulating neurotransmission
H_4	mast cells, eosinophils, T cells, dentritic cells	regulating immune responses

Smooth ms → BVs → Relaxat; Bronchi → Constr
Brain Cho Contri CF ; CNS
Smooth ms.
↓ NE, ACh Secretion ; presynaptic autoRs → ↓ His!

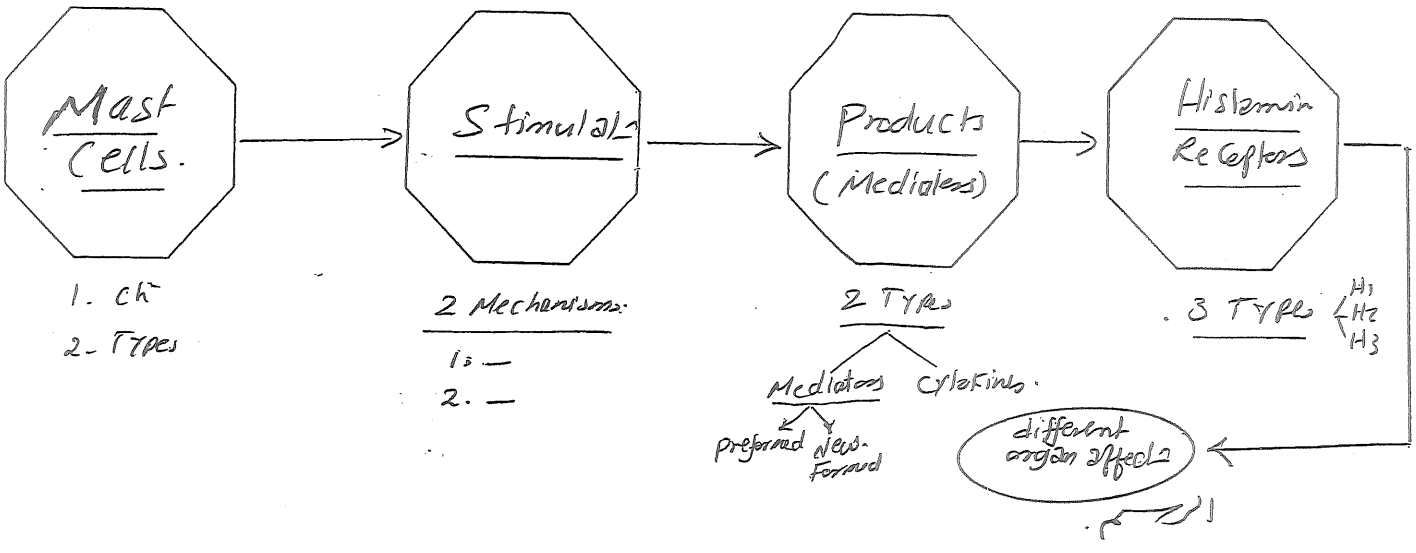
NB Effects of release of Mediators & Cytokines: (التأثيرات)

المقدمة

1. IL4 → ++ B Cell → ↑ IgE
2. IL5 → ++ Eosinophils
3. IL6 → . ↑ IgE
 . ++ TC growth & maturation
4. IL8 → ++ Neutrophils chemotaxis.
5. TNF-α → ++ All:
 . Neut.
 . Eos
 . Fibroblast
 . Phagocytosis.

[. Blood → Agranulated (monocyte, lymphocyte)
. Skin → granulated.
الفرق بينهما بالخلية
Blood & Skin: Mast Cells.

حتة الخلية



Mast cell diseases

① Cut. immediate hypersensitivity react., Urticaria (IgE)

② AD

③ Allergic CD

④ B.P

⑤ PS: ± develop d.t mast cell mediated vascular alterat.

⑥ PRV → Mast Cell → PG → itching

⑦ Fibrotic diseases — Sclerderma, GVHD

Host T Cells → Lymphokines act on mast cell then mast cell → ++ fibrosis (IL)

PCT

ⓐ UVR → ++Complement → Anaphylatoxins

ⓑ ..then Histamine → Released

ⓒ ++ Fibroblast mitogenesis

ⓓ Collagen Synth.

Hypertrophic

⑧ NF*

⑨ → Scars & Keloid

⑩ wound healing:

1. ++ Collagen Synth
2. ++ Vascular permeab.
3. Angiogenesis

⑪ Mastocytosis.

⑫ Necrotizing Vasculitis.

Mastocytosis

updated 2017

.. Def. disorder (ch B) Mast cell prolif. & Accumulat. within many organs, Most Commonly the skin.

Etiopathogenesis : Mast cells Express cell receptors called : c-Kit (CD117) receptors (on) are Rs for stem cell. factor (SCF, its Ligand) ∴ is important for Mast cell prolif.

- Mutat in c-Kit receptors → (unControlled) Stimul of receptors → prolif. & Accumulat in various tiss.
- Inhibiting Tyrosine Kinase receptor ≡ Imatinib may Treat mastocytosis

Classificat of Mastocytosis

↓

3 classifications :

A. WHO Classificat : (2001)

Cut. Mastocytosis (5)

- Commonest in children ← . urticaria pigmentosa
- Commonest in Adult ← . Maculopapular
- Rare Types →
 - . Diffuse Cut.
 - . TMEP
 - . Mastocytoma .
 - . Erythrodermic

Cut Systemic ← Mast cell leuk or Sarcoma Extra Cut.

Systemic mastocytosis

- . Indolent
- . Aggressive
- . Mast cell leukemia
- . Mast cell Sarcoma
- . Ass. with clonal Hematological non Mast cell lineage dis. (AHNMD)
- . Extra Cut. mastocytoma.

- **Age**: 2 peaks:

(75%) **Infancy & Early-Childhood** — **Adulthood** (25%) (30–50 yrs)

Fate ↓

- 50% → resolut°
- 40% → reduct°
- 10% → persist.

at puberty

usually persistent

75% of Mastocytosis cases occurs at infancy or Early Childhood

- **Sex**: M = F.

C/P of Mastocytosis

A Symptoms of Mastocytosis:

1. **There may be:** (more in Adult type)
 - pruritus
 - Flushing
 - Abd. pain
 - diarrhoea
 - Palpitat°
 - dizziness
 - Syncope
 - shock.

 → all are physiological Effects of Histamine & mast cell mediators release.

2. **If there are:** fever, wt loss, malaise, boneache, Epigastric distress & Cognitive disorganizat° indicating → Extracut. dis.

- **Symptoms may be ppt by:**
 1. Exercise
 2. Heat
 3. local Trauma
 4. Alcohol
 - **Drugs:**
 - Alcohol
 - Salicylates
 - NSAIDs
 - Narcotics
 - systemic anaesth.

B Cut. lesions of Mastocytosis:

- Childhood Mastocytosis (<15 y.)
 1. Generalized (60-90%) → Maculopapular or UP
 2. localized (5-20%) → Solitary Mastocytoma.
 3. Diffuse Cut.
- Adulthood (>15 y.)
 1. Generalized Maculopapular (Commonest)
 2. TMEP
 3. Diffuse Cut.

A. Childhood Mastocytosis:

1. Urticaria Pigmentosa (UP) (Childhood generalized Maculop. Mastocytosis)

- .incid: Commonest type affecting the children (60-90%)
- .onset: Infancy (1st year)
- .lesion: Maculopapular:
 - Multiple, generalized, small reddish-brown
 - Usually on trunk but may affect Head & neck
 - on Rubbing → urticaria (Darier's Sign) followed by → refractory period of (2-3 d).
- .varieties: (1) Nodular (2) Vesicular
 (3) Bullous UP. → bullae + UP lesions.
 (4) Xanthelasmoid UP → pale-yellow lesions

Bullous UP & Bullous Mastocytosis

- Fate: . 50% → resolve at puberty
 . 40% → ↑↑ " "
 . 10% → persist.

2 Localized Mastocytosis → "Solitary Mastocytoma"

. Incid: 15–20% of mastocytosis cases in children (2nd most common).

- onset: infancy or birth
- lesion: → Solitary Nodule: (± 2-3 Nodules.) or plaque.
 - Yellow-tan
 - usually on wrist but may be at Trunk & Neck. ↗ "Dorsal Hand"
 - Rubbing → +ve Darier sign & may be Flushing or even shock
- invol: → ≃ 10 yrs.

3. Diffuse Cut. Mastocytosis: (Erythrodermic or Xanthelasmoid Mastocytosis)

- onset: infancy.
- lesion: Skin ch BY: (3) –
 - Hyperpigm: → generalized, brownish-orange discoloration.
 - Infiltration: → doughy or boggy sensation.
 - Lichenification & ± diffuse blistering".
- Varieties: → diffuse cut. blistering may occur so called « Bullous Mastocytosis ».

(Sep.'s)

West

All infancy

(1) UP: reddish-brown macules on Trunk → +ve Darier
. varieties but:

(2) Solitary Mast: reddish brown
(1-3) Nodule at dorsum rest → +ve Darier . onset: ✓ resolve at: ✓

(3) Diffuse but:
- Infiltr
- Hyperpigm
- Lichenfical
- Bullous.

B. Adulthood Mastocytosis:

(30-50Y)

1. Generalized → Maculopapular Mastocytosis.

- Hyperpigm.
- Telangiect.
- -ve Darier
- persist.

- Incid: Commonest Type in adults.
- lesion: reddish-brown macules & papules usually on Trunk & proximal Extremities.
 - (2) may show → Hyperpigm. & Telangiectasia.
- Fate: → usually persistent.

Darier Sign: less common

2. Telangiectasia Macularis Eruptiva Perstans: (TMEP)

"Paucicellular Mastocytosis"

- Incid: 2nd Commonest Type in adults.
- lesion: Macules & Patches with Telangiectasia & non significant Hyperpigm.
- Fate: resistant & persistent.

Darier Sign: barely detectable.

3. Diffuse Cut. → as before but appears on adulthood.

	Childhood Mastocytosis	Adulthood Mastocyt
• Incid:	Most Common (75%)	• less Common
• lesion:	Commonest Types: (1) UP (2) Mastocytoma.	• Commonest types: (1) Generalized Macular Papular (2) TMEP.
• Darier Sign:	• usually +ve	• usually: -ve.
• Systemic manifs & affect:	• less Common	• More Common.
• Fate	• UP → -ve < Pubert × (50%) Mastocytoma ↓ for ↓	• Persistent.

Histopathology of Cut. Mastocytosis:

إحتياطات أخذ العينة:

① Inject local anaesth.
But < without epinephrin & around the lesion

② avoid Trauma or Crushing of the Specimen.

all will → Mast Cell degranu: & -ve results

③ تطبيق محلول ملح وليس في كورسالين

④ إصبغ < Giemsa or TB Leider to detect mast Cell granules.

Leder stain: intact mast cell grans.

Results:

Monoclonal antibodies against < Tryptase or CD117 (detect about Mast Cells) ← Gold type that contain few mast cell.

at Papillary dermis:

- UP → Mast Cell Chasy.
 - "T.Blue → purple" → Metachromatic grs
 - Nuclei are rounded with surrounding ample Cytoplasm → Fried Egg appearance.
- TMEP → Mast Cells are brick or spindle shaped.
- Nodular up. → dense aggregate of Mast Cells may affect entire dermis → S.C.T.

- Diffuse Mastocytosis: dense, band like subepid; Mast Cell infilt.
- Bullous Mastocytosis: subepid. bullae.

Lab. Inv. For Systemic Mastocytosis

① Serum Tryptase

② Urinary: Histamine, N-Methyl histamine, N-methyl Imidazole acetal, PGD2

③ BMA: if ↑ Tryptase → Hsm (monoclonal)

Lab Invs

- Mild Cut → No lab abnormalities
- Sever Cut
 - (1) Urine
 - Histamine
 - N-methyl histamine
 - N-Methyl-Imidazole acetate
 - → Sens. & Specific
 - PGD2 (کرسٹوز)
 - ↑ Tryptase (Serum)
 - [یکسہ متاثر کرنے والے خلیوں میں / Insect bites سے]
 - 2. CBC → anemia, ↑ WBC, Eos.
 - 3. BMA → panCyt. or Tryptase, HSM
- Systemic
 - as Sever Cut +

Systemic Mastocytosis

WHO

- Cut. mastocytosis
- Systemic "
 - Mast Cell Leukemia
 - Mast Cell Sarcoma
 - Extra Cut. Mastocytoma

Indolent
Aggressive
Ass. ē Clonal-Hemato-logical non-mast cell lineage dis

(SM-AHNMD)

WHO Criteria of Systemic Mastocytosis

- Major: Mast Cell infilt → Multifocal (>15 cells in aggregates) BM &/or extracut-affect
- Minor:
 - > 25% of These ↑ mast cells are → Spindle or Atypical
 - Tryptase > 20 ng/ml
 - A Codon 816 KIT Mutat
 - Aberrant expression of CD25 &/or CD2

- For diagnosis
 1 J + 1 M or 3 minor.

NB

. Darier sign

(1.) +ve in 2 dis → mastocytosis, Leukemia cutis

(2.) -ve in Adulthood mastocytosis ??

d.t low concentrat- of infiltrating mast cells e.g

. Solitary mastocytoma : 140 fold
. Urticaria pigmentosa : 40 "
. Adult mastocytosis : 8 "

} The NL skin.

so → TM Ep, Generalized Adult mast. Called ((Pauci Cellular Mastocytosis))

Treatment

(Symptomatic ; No Cure)

(1.) Reassurance : in childhood Type

(2.) Avoid mast cell degranulators

. Alcohol, Aspirin, NSAIDs, Narcotics & (Not local) Anaesthesia

. Heat, Fricf

"Anaphylaxis" ← agg → Systemic

(3.) local :

. Cs : potent & superpotent ; ± under occlusion

. IL Cs

(4.) oral :

. Antihistamines (H1 & H2 blockers)

. mast cell stabilizers

. Systemic Cs

. PUVA.

(5.) Aggressive (Systemic mastocytosis

- Imatinib methylate of
- IFN-α 2.b.